Comparative Outcomes of Laparoscopic Surgery for Superior Mesenteric Artery Syndrome: A Retrospective Cohort Study

Ann. Ital. Chir., 2026: 1–9
https://doi.org/10.62713/aic.4748

Baran Demir[1], Ulaş Aday[2], Abdulkadir Akbaş[3], Abdullah Oğuz[2]

[1]Department of General Surgery, Tunceli State Hospital, 62000 Tunceli, Turkey
[2]Department of General Surgery, Dicle University Faculty of Medicine, 21280 Diyarbakir, Turkey
[3]Department of General Surgery, Ceylanpınar State Hospital, 63570 Şanlıurfa, Turkey

AIM: Superior mesenteric artery syndrome (SMAS) is a rare but potentially debilitating cause of proximal intestinal obstruction resulting from vascular compression of the third portion of the duodenum. While surgical intervention is indicated in patients unresponsive to conservative therapy, comparative evidence between laparoscopic and open approaches remains limited. This study aimed to evaluate perioperative and long-term outcomes of laparoscopic versus open duodenojejunostomy (DJ) in patients with SMAS.

METHODS: In this retrospective cohort study, 13 consecutive patients diagnosed with SMAS and treated surgically at Dicle University Hospital, a tertiary referral center in Diyarbakır, Turkey between January 2017 and September 2024 were analyzed. Patients were stratified into laparoscopic and open surgery groups. Demographic characteristics, operative variables, postoperative outcomes, and follow-up data including body mass index (BMI) changes and symptom resolution were compared between the groups.

RESULTS: A total of 13 patients (9 females, 4 males) with a median age of 26 years (range: 17–59) were included. Six patients underwent laparoscopic duodenojejunostomy, while seven underwent open procedures. Baseline demographic and clinical characteristics were generally comparable between the groups, with the exception of symptom onset time, which was significantly longer in the laparoscopic group (44.3 ± 16.5 vs. 22.0 ± 16.1 months, $p = 0.032$). Operative time did not differ significantly between laparoscopic and open surgery (103.3 ± 68.8 vs. 95.0 ± 52.0 minutes, respectively; $p > 0.05$). The laparoscopic group demonstrated a significantly shorter hospital stay (median: 5.5 [3–6] days vs. 7 [6–9] days; $p = 0.008$). During follow-up, mean BMI values increased in both groups, with no statistically significant between-group differences at the assessed time points. Postoperative symptoms persisted in one patient in the open surgery group and none in the laparoscopic group ($p = 1.000$). Postoperative symptom resolution was achieved in 12 of 13 patients (92.3%), and no symptom recurrence was observed during follow-up.

CONCLUSIONS: In this small retrospective cohort, laparoscopic duodenojejunostomy was feasible and associated with a shorter hospital stay compared with open surgery. Both approaches resulted in symptom improvement and BMI gain during follow-up. Larger prospective studies are required to clarify comparative long-term effectiveness and establish optimal surgical selection criteria.

Keywords: superior mesenteric artery syndrome; duodenojejunostomy; laparoscopic surgery; open surgery; comparative study; surgical outcomes

Introduction

Superior mesenteric artery syndrome (SMAS) is a rare clinical condition caused by the compression of the third part of the duodenum between the aorta and the superior mesenteric artery (SMA), which branches from the aorta at a narrow angle. Although the syndrome was first described by Rokitansky [1] in 1842, it is often referred to as "Wilkie's syndrome" because Wilkie [2,3] reported the condition in 1921 and subsequently published a large case series in 1927. There is a significant association between rapid weight loss and the development of SMAS. The pathophysiology is thought to involve a decrease in the aortomesenteric angle (normal: 38–56°) to <25° and a reduction of the aortomesenteric distance (normal: 10–20 mm) to <8 mm following rapid weight loss [4]. Depletion of mesenteric fat tissue between the SMA and aorta leads to narrowing of the angle between these structures and results in duodenal compression [5]. Apart from rapid weight loss, other causes of SMAS include a history of spinal surgery, psychiatric disorders, cancer, malabsorption, and tuberculosis [4,6].

The incidence of superior mesenteric artery syndrome (SMAS) has been reported to range between 0.1% and 0.3%. Clinical knowledge and awareness regarding the disease are limited, and diagnosis is often delayed. Postprandial abdominal pain, bilious vomiting, loss of appetite, and early satiety may further worsen the clinical picture [7,8]. The primary imaging modality for diagnosis is mesenteric angiography performed with abdom-

Submitted: 9 May 2026 Revised: 16 June 2026 Accepted: 24 July 2026 Published: 26 November 2026
Correspondence to: Baran Demir, Department of General Surgery, Tunceli State Hospital, 62000 Tunceli, Turkey (e-mail: bdemir.2135@gmail.com).
Editor: Guiyu Wang

inal computed tomography (CT). In addition to abdominal CT, upper gastrointestinal (GI) endoscopy and contrast-enhanced esophagus–stomach–duodenum radiography performed under fluoroscopy are among the diagnostic methods [5]. The initial recommended approach in the management of SMAS is conservative treatment. The primary goal is to restore mesenteric fat tissue through weight gain and thereby increase the aortomesenteric angle. In a series of 80 patients, the success rate of this approach was reported as 73.3%, although the risk of recurrence was noted [4]. Additionally, prolonged and repeated hospitalizations in conservative treatment impose a significant financial burden on both the patient and the healthcare system. Surgical intervention may offer effective symptom relief in patients who do not respond to conservative treatment [9].

When conservative management is inadequate, surgical procedures become the main treatment modality. These procedures include the Strong's procedure, which involves division of the ligament of Treitz, gastrojejunostomy, and duodenojejunostomy (DJ) [10]. Currently, duodenojejunostomy stands out as the most commonly performed method. Due to the widespread use of minimally invasive techniques in abdominal surgery, increasing experience, and the advantages they offer, this approach has become widely accepted in the treatment of this rare condition as well [7]. However, studies involving large case series and long-term follow-up remain limited. Although laparoscopic duodenojejunostomy has increasingly been adopted because of the advantages of minimally invasive surgery, direct comparative evidence between laparoscopic and open approaches remains scarce. Most published reports consist of case reports or small case series without direct comparison groups. Consequently, the relative perioperative and long-term outcomes of these two approaches remain insufficiently defined, providing the rationale for the present study. In this study, we aimed to compare the early and long-term outcomes of patients with SMAS who underwent laparoscopic versus open surgical procedures.

Methods

Study Design and Population

Data from patients with SMAS who underwent surgery because of failure of medical treatment between January 2017 and September 2024, at Dicle University Hospital, a tertiary referral center in Diyarbakır, Turkey were retrospectively reviewed. Clinical, radiological, operative, and follow-up data were obtained through retrospective review of electronic and written medical records. Patients aged 17 years and older, with complete data available, and with a minimum follow-up period of 12 months were included. Patients with comorbidities severe enough to preclude surgical intervention, those with synchronous pathologies causing duodenal obstruction, and those with a follow-up period of less than one year were excluded.

Data Collection

Demographic data—including age, sex, comorbidities, American Society of Anesthesiologists (ASA) score, body mass index (BMI, kg/m^2), presenting symptoms and duration, and albumin levels—were recorded. Additional pathologies detected in imaging studies were also identified and documented. Operative variables evaluated included surgical procedure, operative time, blood loss, and additional surgical procedures. Postoperative outcomes included length of hospital stay, persistence or regression of symptoms, and early/late complications.

Symptom resolution was defined as complete or near-complete disappearance of preoperative symptoms, including nausea, vomiting, postprandial abdominal pain, and loss of appetite, during follow-up. Persistent symptoms were defined as the continued presence of one or more preoperative complaints after surgery. Early complications were defined as adverse events occurring within 30 days after surgery, whereas late complications were defined as events occurring beyond 30 days. Recorded complications included anastomotic leak, postoperative ileus, hospital readmission, reoperation, and persistent postoperative symptoms. Postoperative complications were retrospectively classified according to the Clavien–Dindo classification system.

Preoperative Preparation

The diagnosis was clinically and radiologically confirmed in all patients. On arterial-phase abdominal CT scans, diagnosis was supported by an aortomesenteric angle <25°, an aortomesenteric distance <8 mm, and radiological evidence of duodenal compression with proximal duodenal dilatation (Fig. 1). All patients underwent preoperative endoscopy for differential diagnosis, and findings indicating SMAS (such as bile retention, duodenal dilation, and external compression of the third portion) were documented. Esophagus–stomach–duodenum (ESD) contrast radiography was performed in four patients based on the gastroenterologist's preference (Fig. 2). After expert evaluation by a gastroenterologist, all patients received at least 6–8 weeks of optimal conservative treatment. An insufficient response to conservative treatment was defined as persistent obstructive symptoms, including vomiting and abdominal pain, continued weight loss, or inability to maintain adequate oral nutritional intake despite treatment. Patients with insufficient response to conservative therapy were discussed in a multidisciplinary board consisting of a gastrointestinal surgeon, gastroenterologist, and radiologist, and the decision for surgery was made accordingly. Patients with persistent preoperative malnutrition received enteral (jejunal tube) or parenteral nutritional support, and fluid–electrolyte imbalances were corrected prior to surgery.

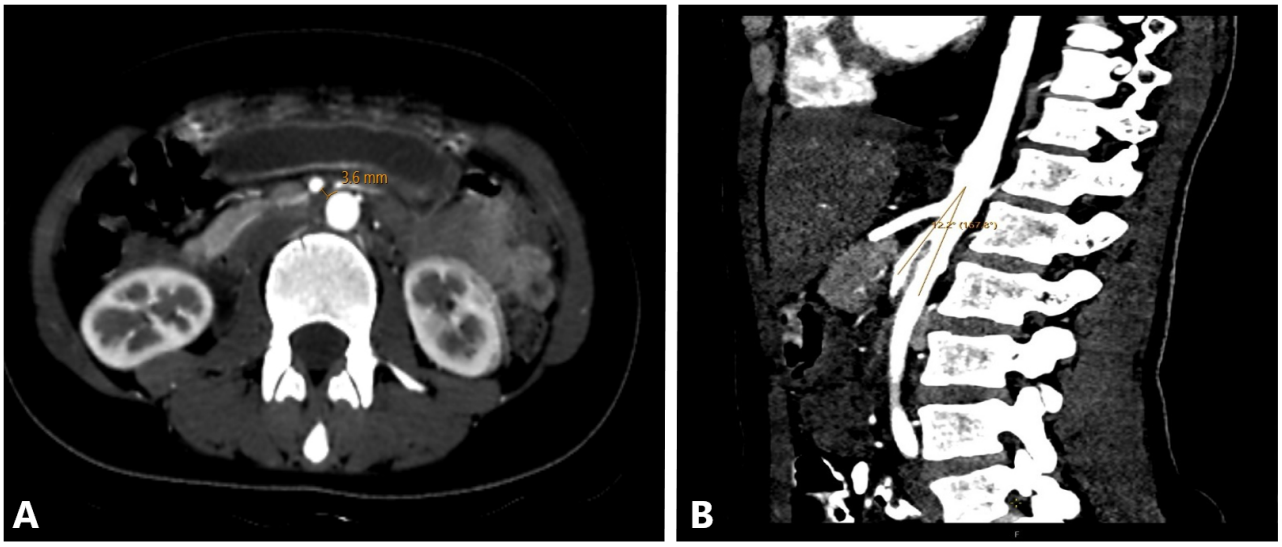

Fig. 1. Arterial-phase abdominal computed tomography (CT) images. (A) Aortomesenteric distance. (B) Aortomesenteric angle.



Fig. 2. Esophagus–stomach–duodenum (ESD) contrast radiography demonstrating dilatation of the proximal duodenum with abrupt narrowing at the third portion of the duodenum (arrow), consistent with superior mesenteric artery syndrome.

Surgical Procedure

Surgical intervention was considered in patients who failed conservative management, had persistent obstructive symptoms, severe weight loss, or recurrent hospital admissions. The choice of surgical technique was based on the patient's clinical status, anatomical findings, surgeon experience, and intraoperative evaluation. Duodenojejunostomy was preferred because it is considered the most effective and widely accepted surgical treatment for Superior Mesenteric Artery Syndrome, with high success rates reported in the literature.

Because of the retrospective nature of the study, patients were not randomized to laparoscopic or open surgery. The choice of operative approach was individualized according to surgeon preference, anatomical considerations, associated vascular or gastrointestinal pathology, previous abdominal interventions, and intraoperative findings. Therefore, the comparison between groups should be interpreted as exploratory and hypothesis-generating rather than a definitive assessment of superiority or equivalence.

Laparoscopic DJ Procedure

Patients undergoing laparoscopic duodenojejunostomy were positioned in the French split-leg position, with the surgeon on the patient's left, the camera assistant between the legs, and the assistant surgeon on the right. After establishing pneumoperitoneum via a Veress needle at the umbilicus, a 10-mm camera port was placed. Under direct visualization, the remaining working ports were inserted in appropriate anatomical positions.

The procedure began with elevation of the omentum and transverse colon mesentery. An avascular window was opened above the ileocolic vascular pedicle and expanded to visualize the second and third portions of the duodenum. Approximately 30 cm distal to the ligament of Treitz, a jejunal loop was selected for duodenojejunal anastomosis. Enterotomy was performed on both loops, followed by placement of suspension sutures using 2/0 absorbable monofilament (polydioxanone). A 60-mm laparoscopic linear sta-

pler was introduced through a 12-mm port, and a side-to-side duodenojejunostomy was created in standard fashion (Fig. 3). The enterotomy site was then closed with a single-layer continuous suture using 4/0 barbed polydioxanone. A Jackson-Pratt drain was selectively placed in the pelvis according to intraoperative findings and the surgeon's discretion, and the fascia of the 10-mm and 12-mm port sites was closed with 2/0 absorbable monofilament sutures.

Open DJ Procedure

For patients undergoing open duodenojejunostomy, the abdomen was entered through a midline incision. After elevating the omentum and transverse colon mesentery, the second and third portions of the duodenum were mobilized. A jejunal loop approximately 30 cm distal to the ligament of Treitz was selected for anastomosis. Following enterotomy, a side-to-side duodenojejunostomy was performed using a 45-mm linear stapler. The enterotomy site was closed with a double-layer continuous technique using 4/0 barbed polydioxanone. A Jackson-Pratt drain was placed in the pelvis when indicated, and the fascia was closed continuously with No. 1 absorbable monofilament suture. On postoperative day 2, oral fluid intake was initiated and gradually advanced based on tolerance. Similar postoperative management protocols, including analgesic management, drain removal, and discharge criteria, were applied in both groups.

Follow-up

Patients were evaluated every 3 months during the first postoperative year and every 6 months thereafter. Patients who remained asymptomatic for more than 3 years were discharged from routine follow-up according to institutional practice. However, not all patients reached a 3-year follow-up period because patient enrollment continued until September 2024. Follow-up duration was defined as the interval between surgery and the most recent available clinical evaluation for each patient. During follow-up, improvement of preoperative symptoms, nutritional status, ongoing clinical condition, and BMI values were assessed. All outcomes were compared between the laparoscopic and open surgery groups.

Statistical Analysis

Statistical analyses were performed using jamovi version 2.6 (The jamovi Project, Sydney, Australia; https://www.jamovi.org). Continuous variables were assessed for normality using the Shapiro–Wilk test. Because of the small sample size and the potential influence of outliers, continuous variables are presented as both mean ± standard deviation and median (minimum–maximum). Mean values were provided to facilitate comparison with previous studies, whereas median values were included to better describe data distribution in this small cohort. Comparisons between two independent groups were performed using the Mann–Whitney U test for non-normally distributed variables (number of days of hospitalization and follow-up duration; Shapiro–Wilk test $p < 0.05$) and Student's t-test for normally distributed variables (all other continuous variables; Shapiro–Wilk test $p > 0.05$). Categorical variables are presented as frequencies and percentages and were compared using Fisher's exact test because of the small sample size and low expected cell counts. A p value < 0.05 was considered statistically significant.

Results

A total of 13 patients (9 females and 4 males) underwent surgery for SMAS. The median age of the study population was 26 years (range: 17–59). The most common presenting symptom was weight loss, observed in 11 patients (84.6%). Nausea and postprandial pain were each reported in 9 patients (69.2%), followed by vomiting in 6 patients (46.2%). The median duration of symptoms was 30.0 months (range: 4–60). The mean time from symptom onset to surgery was 22 ± 16.1 months in the open surgery group and 44.3 ± 16.5 months in the laparoscopic group. All patients underwent abdominal CT angiography and upper gastrointestinal endoscopy. Seven patients underwent open surgery, while six patients underwent laparoscopic surgery. Demographic and clinical characteristics and preoperative findings of the groups are presented in Table 1.

In the laparoscopic group, the mean aortomesenteric angle was 14.2 ± 2.7°, and the aortomesenteric distance was 3.5 ± 1.9 mm. In the open surgery group, the mean aortomesenteric angle was 14.4 ± 4.1°. Baseline demographic and clinical characteristics were generally comparable between the two groups. However, symptom onset time was significantly longer in the laparoscopic group than in the open surgery group (44.3 ± 16.5 vs. 22.0 ± 16.1 months, $p = 0.032$). No statistically significant differences were observed in the remaining baseline variables. Additional surgical interventions were performed in one patient with Nutcracker syndrome, one patient with median arcuate ligament syndrome (MALS), and one patient with refractory duodenal ulcer.

Among the seven patients who underwent open surgery, two received additional procedures (renal vein decompression with a polytetrafluoroethylene (PTFE) graft for Nutcracker syndrome and ligament division for MALS). In the laparoscopic DJ group, one patient underwent bilateral truncal vagotomy and antrectomy as definitive treatment for refractory duodenal ulcer. The mean operative time was 103.3 ± 68.8 minutes in the laparoscopic group and 95.0 ± 52.0 minutes in the open group ($p = 0.945$). Estimated intraoperative blood loss was comparable between the laparoscopic and open surgery groups, with no statistically significant difference observed (median: 25 [15–75] mL vs. 30 [15–75] mL, respectively; $p = 0.772$). Length of hospital stay was shorter in the laparoscopic group: 5.5 days (range: 3–6) compared with 7 days (range: 6–9) in the open surgery

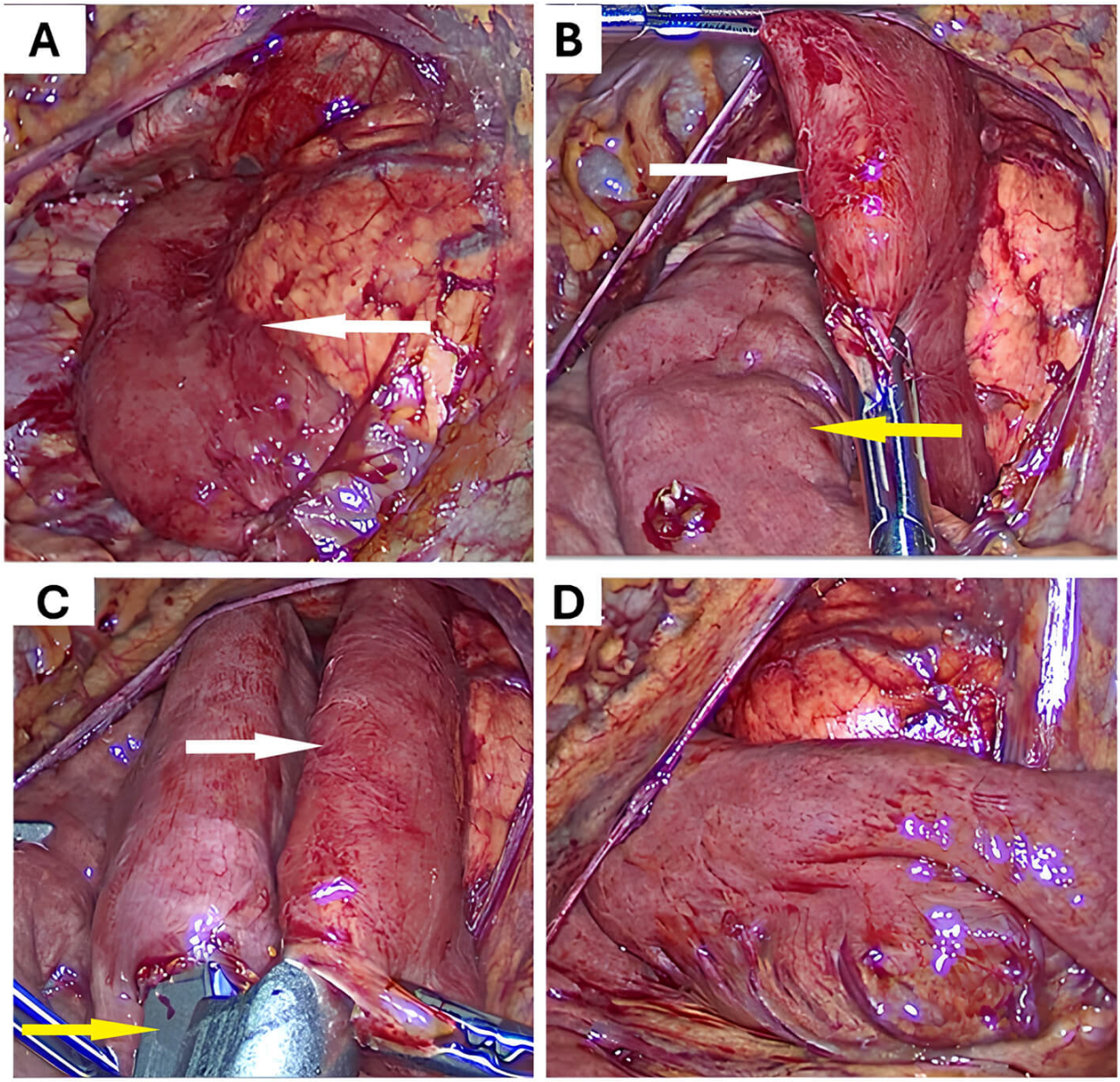

Fig. 3. Laparoscopic duodenojejunostomy (DJ) steps (intraoperative images). (A) Opening the avascular plane of the right/transverse mesocolon to expose the second and third portions of the duodenum (white arrow). (B) Enterotomy of the jejunum and duodenum, demonstrating the duodenum (white arrow) and jejunum (yellow arrow). (C) Placement of a linear stapler into the jejunum and duodenum for a side-to-side anastomosis, showing the duodenum (white arrow) and linear stapler (yellow arrow). (D) Final appearance of the completed side-to-side duodenojejunostomy.

group (p = 0.008). Operative and postoperative outcomes for both groups are summarized in Table 2.

The median (minimum–maximum) follow-up duration was 20.0 (13.0–97.0) months in the laparoscopic group and 32.0 (14.0–104.0) months in the open surgery group. BMI values in the laparoscopic group at the preoperative period, 6th month, and 12th month were 18.7 ± 1.8, 19.9 ± 1.9, and 21.7 ± 2.2 kg/m^2, respectively. In the open surgery group, BMI values at the same time points were 17.1 ± 2.0, 18.1 ± 1.8, and 19.8 ± 1.4 kg/m^2. No significant differences were observed between the groups (Table 3).

No mortality or major postoperative complications were observed in the study population. Specifically, no patient developed an anastomotic leak, postoperative ileus, required reoperation, or was readmitted during follow-up. In the open surgery group, one patient experienced persistent postprandial pain during the early postoperative period; however, symptoms regressed with conservative management and no additional intervention was required. According to the Clavien–Dindo classification, this event was classified as a Grade I complication. No Grade II–V complications were observed in either group.

Table 1. Demographic, clinical, and preoperative data of the groups.

	Open (n: 7)	Laparoscopic (n: 6)	*p* value
Age (years)	24.9 ± 6.64	31.2 ± 14.8	0.329
	26.0 (17.0–34.0)	26.0 (18.0–59.0)	
Gender			1.000
Male	2 (28.6)	2 (33.3)	
Female	5 (71.4)	4 (66.7)	
ASA score			1.000
1	2 (28.6)	2 (33.3)	
2	5 (71.4)	4 (66.7)	
Comorbidity	2 (28.6)	1 (16.7)	1.000
Epilepsy	1 (14.3)	0 (0.0)	
Mental retardation	0 (0.0)	1 (16.7)	
Tuberculosis	1 (14.3)	0 (0.0)	
Smoking	2 (28.6)	1 (16.7)	1.000
Symptom onset time (months)	22.0 ± 16.1	44.3 ± 16.5	0.032
	12.0 (4.0–48.0)	49.0 (24.0–60.0)	
Preoperative albumin value (g/L)	40.4 ± 5.4	42.1 ± 5.7	0.597
	40.1 (31.4–47.4)	43.0 (34.0–48.0)	
Preoperative esophagus-stomach-duodenum contrast radiography	1 (14.3)	3 (50.0)	0.266
Preoperative endoscopy	7 (100.0)	6 (100.0)	-
Endoscopic biopsy	1 (14.3)	2 (33.3)	0.559
Endoscopic findings			
Alkaline reflux	6 (85.7)	6 (100.0)	1.000
Duodenal ulcer	1 (14.3)	2 (33.3)	0.559
External compression on the duodenum	7 (100.0)	6 (100.0)	-
Preoperative CT	7 (100.0)	6 (100.0)	-
Aorto mesenteric angle (°)	14.4 ± 4.1	14.2 ± 2.7	0.889
	14.5 (8.0–20.0)	14.2 (10.5–19.0)	
Aorto mesenteric distance (mm)	3.3 ± 0.9	3.5 ± 1.9	0.834
	3.5 (1.5–4.5)	2.7 (1.8–6.0)	
Preoperative symptoms			
Nausea	5 (71.4)	4 (66.7)	1.000
Vomiting	3 (42.9)	3 (50.0)	1.000
Postprandial pain	4 (57.1)	5 (83.3)	0.559
Loss of appetite	1 (14.3)	0 (0.0)	1.000
Weight loss	7 (100.0)	4 (66.7)	0.192
Associated morbidity			1.000
None	5 (71.4)	5 (83.3)	
Nutcracker syndrome	1 (14.3)	0 (0.0)	
Duodenal ulcer	0 (0.0)	1 (16.7)	
Median arcuate ligament syndrome	1 (14.3)	0 (0.0)	

-, no between-group variability. Continuous variables are presented as mean ± standard deviation and median (minimum–maximum). Comparisons between continuous variables were performed using Student's *t*-test or Mann–Whitney U test according to data distribution. Categorical variables are presented as frequencies and percentages and were compared using Fisher's exact test. ASA, American Society of Anesthesiologists; CT, computed tomography.

Discussion

SMAS was first described by Rokitansky in 1842 [1]. Later, in 1907, Bloodgood [11] reported the latero-lateral duodenojejunostomy as a surgical treatment. Wilkie [2,3] initially reported this condition in 1921, followed by a comprehensive case series of 75 patients in 1927 [2], and therefore the condition is also known as Wilkie's syndrome. The fundamental mechanism in SMAS involves narrowing of the aortomesenteric space/angle due to loss of mesenteric fat following weight loss, leading to compression of the third portion of the duodenum. Although an aortomesenteric angle <25° (normal: 38°–56°) and an aortomesenteric distance <8 mm (normal: 10–20 mm) are considered diagnostic thresholds, radiological confirmation of duodenal compression, duodenal dilation, and gastric stasis is critical for differentiating SMAS from conditions such as anorexia and

Table 2. Operative and postoperative outcomes for both groups.

	Open (n: 7)	Laparoscopic (n: 6)	*p* value
Surgical procedure			1.000
DJ	5 (71.4)	5 (83.3)	
DJ + renal vein decompression	1 (14.3)	0 (0.0)	
DJ + bilateral truncal vagotomy + antrectomy	0 (0.0)	1 (16.7)	
DJ + MAL division	1 (14.3)	0 (0.0)	
Duration of surgery (min)	95.0 ± 52.0 70.0 (45.0–180.0)	103.3 ± 68.8 87.5 (35.0–230.0)	0.701
Drain use	6 (85.7)	5 (83.3)	1.000
Postoperative esophageal-stomach-duodenum radiograph	4 (57.1)	3 (50.0)	1.000
Postoperative symptoms	1 (14.3)	0 (0.0)	1.000
Number of days of hospitalization	7.0 ± 1.0 7.0 (6.0–9.0)	5.1 ± 1.1 5.5 (3.0–6.0)	0.008
Estimated blood loss (mL)	37.1 ± 22.0 30 (15–75)	31.7 ± 21.8 25 (15–75)	0.772

Number of days of hospitalization was compared using the Mann–Whitney U test; all other continuous variables were compared using Student's *t*-test. MAL, median arcuate ligament; DJ, duodenojejunostomy.

Table 3. Follow-up data of groups.

	Open (n: 7)	Laparoscopic (n: 6)	*p* value
Preoperative BMI (kg/m^2)	17.1 ± 2.017.2 (15.1–21.0)	18.7 ± 1.818.8 (16.4–22.0)	0.138
6th month BMI (kg/m^2)	18.1 ± 1.818.0 (16.3–21.6)	19.9 ± 1.8919.6 (17.6–23.1)	0.101
1st year BMI (kg/m^2)	19.8 ± 1.420.2 (18.2–22.2)	21.7 ± 2.222.0 (17.9–24.2)	0.101
Follow-up duration (months)	38.2 ± 30.832.0 (14.0–104.0)	34.0 ± 31.820.0 (13.0–97.0)	0.534

Follow-up duration was compared using the Mann–Whitney U test; all other continuous variables were compared using Student's *t*-test. BMI, body mass index.

bulimia nervosa, cyclic vomiting syndrome, gastroparesis, and functional dyspepsia [12,13]. For this reason, in addition to contrast-enhanced arterial-phase abdominal CT, upper gastrointestinal endoscopy and contrast-enhanced ESD imaging should be performed preoperatively to support the diagnosis. Consultation with psychiatry and gastroenterology may also be useful in excluding differential diagnoses. In our study, all patients underwent upper GI endoscopy, which demonstrated duodenal compression and dilation of the proximal duodenum and stomach.

Although anatomical variations at the origin of the SMA and high insertion of the ligament of Treitz have been implicated in the etiology of SMAS, the primary contributing factor is generally considered to be weight loss and low BMI [14]. Nevertheless, cases with normal BMI have also been reported [9,15]. In our study population, six patients had BMI values within the normal range.

Most publications on SMAS consist of case reports and small case series. Reports have originated from various regions worldwide, suggesting that the syndrome is not associated with a particular ethnic background. Notable contributions include Sabry et al.'s [6] series of 11 cases, Lu et al.'s [7] series of 66 patients, and Jain et al.'s [15] series of 22 patients. Although SMAS is often reported to be more common in young adolescent females, the median age in our study was 26.0 years (range: 17–59). Our oldest patient was 59 years old, which is still considerably younger than the oldest reported patient in the literature (91 years) [9].

Although nausea, vomiting, and abdominal pain are commonly reported symptoms in the literature, weight loss was the most frequent symptom in our study (n = 11; 84.6%). Due to the nonspecific nature of symptoms, diagnosis may be delayed in SMAS. Such delays may increase the risk of aspiration pneumonia due to persistent vomiting, and gastric or duodenal perforation. Some studies have reported that mortality may reach up to 33% when diagnosis is delayed [14,16].

The primary goal in the treatment of SMAS is to relieve extrinsic compression on the third portion of the duodenum. Conservative management aims to promote weight gain, thereby increasing mesenteric fat and widening the aortomesenteric angle. In this context, Lee et al. [4] reported a 71.3% success rate with conservative treatment. Although there is no clear consensus regarding the duration of conservative therapy, several studies recommend that it should not exceed three months [6,17]. In our series, symptoms completely resolved in 12 of 13 patients (92.3%) during the 12-month follow-up after surgery, with no additional intervention required. One patient experienced mild persistent symptoms in the early postoperative period, which regressed with conservative management.

Cienfuegos et al. [14] reported that, during long-term follow-up after duodenojejunostomy, antrectomy was re-

quired in two patients and distal gastrectomy in one patient due to recurrent symptoms. Similarly, other isolated cases in the literature have shown symptomatic improvement after distal gastrectomy as a last resort when symptoms persist despite conservative therapy [16,18,19].

Various surgical procedures have been described for SMAS, including the Strong procedure (division of the ligament of Treitz to mobilize the duodenum) [10], open or laparoscopic gastrojejunostomy, and duodenojejunostomy. Although the Strong procedure has the advantage of not requiring an anastomosis, it may not always be feasible due to the short vascular connections between the inferior pancreaticoduodenal artery and the duodenum [20]. Gastrojejunostomy allows gastric decompression but does not address the primary pathology of duodenal obstruction [21]. Although technically more challenging, duodenojejunostomy is more physiological than gastrojejunostomy and does not carry a risk of bile reflux. In our study, all patients underwent duodenojejunostomy. In the present study, patients undergoing laparoscopic duodenojejunostomy had a significantly shorter hospital stay than those undergoing open surgery (5.5 vs. 7.0 days, $p = 0.008$). This difference may be partly attributable to the minimally invasive nature of laparoscopy, which may reduce abdominal wall trauma and facilitate postoperative mobilization and recovery. However, these potential mechanisms were not directly evaluated in our study, and the observed difference may also have been influenced by patient selection and concomitant surgical procedures.

Several limitations should be acknowledged. First, the retrospective single-center design and small sample size increase the risk of selection bias. Patients were not randomly assigned to laparoscopic or open surgery, and surgical approach was determined according to clinical and anatomical factors as well as surgeon preference. Therefore, unmeasured differences between groups may have influenced perioperative and long-term outcomes. Second, three patients underwent additional procedures because of associated conditions, including renal vein decompression for Nutcracker syndrome, median arcuate ligament release, and bilateral truncal vagotomy with antrectomy for refractory duodenal ulcer. These concomitant interventions may have affected operative duration, postoperative recovery, symptom improvement, and length of hospital stay. The limited sample size reduced statistical power and increased the risk of type II error. Therefore, the absence of statistically significant differences should not be interpreted as evidence of equivalence between laparoscopic and open surgery. Accordingly, the results should be interpreted as exploratory observations rather than evidence of superiority or equivalence between surgical approaches. Additionally, symptom onset time was significantly longer in the laparoscopic group than in the open surgery group. This baseline imbalance may reflect differences in disease chronicity between the groups and may have influenced postoperative outcomes, particularly length of hospital stay and recovery. Therefore, the comparative results should be interpreted with caution. Furthermore, symptom resolution and postoperative BMI gain were assessed retrospectively during routine follow-up rather than through standardized longitudinal outcome assessments.

In addition, because of the retrospective design and the long study period, the exact number of patients diagnosed with SMAS who were managed conservatively and not considered for surgery could not be reliably determined from the available institutional records. Therefore, a complete patient-selection flow diagram could not be constructed, which may limit the transparency of cohort assembly.

Conclusions

In this small retrospective cohort, laparoscopic duodenojejunostomy was associated with a shorter hospital stay and favorable clinical outcomes. Both laparoscopic and open approaches were associated with symptom improvement and postoperative BMI gain during the available follow-up period. Given the retrospective design, limited sample size, and the absence of standardized longitudinal outcome assessments, larger prospective studies with standardized long-term follow-up are needed to confirm these findings and determine the comparative effectiveness of different surgical approaches for SMAS.

Availability of Data and Materials

The data analyzed in this study are available from the corresponding author upon reasonable request.

Author Contributions

Research design: BD, UA. Data curation: BD, UA, AA. Formal analysis: BD, UA, AA. Investigation: BD, AA. Methodology: BD, UA, AA, AO. Supervision: UA, AO. Writing – original draft: BD, UA, AO. All authors have been involved in revising the manuscript critically for important intellectual content. All authors gave final approval of the version to be published. All authors have participated sufficiently in the work to take public responsibility for appropriate portions of the content and agreed to be accountable for all aspects of the work in ensuring that questions related to its accuracy or integrity.

Ethics Approval and Consent to Participate

The requirement for informed consent was waived by the Ethics Committee of Dicle University Faculty of Medicine because of the retrospective and non-interventional nature of the study, and all data were analyzed anonymously. Ethical approval for this study was obtained from the Ethics Committee of Dicle University Faculty of Medicine (Non-Interventional Clinical Research Ethics Committee; approval date: 17 September 2025; meeting no: 321). The study was conducted in accordance with the Declaration of Helsinki.

Acknowledgment

Not applicable.

Funding

This research received no external funding.

Conflict of Interest

The authors declare no conflict of interest.

References

[1] Rokitansky C. Handbuch der pathologischen Anatomie. Braumüller & Seidel: Vienna. 1842.

[2] Wilkie DPD. Chronic duodenal ileus. The British Journal of Surgery. 1921; 9: 204–214. https://doi.org/10.1002/bjs.1800093405

[3] Wilkie DPD. Chronic duodenal ileus. The American Journal of the Medical Sciences. 1927; 173: 643–648.

[4] Lee TH, Lee JS, Jo Y, Park KS, Cheon JH, Kim YS, et al. Superior mesenteric artery syndrome: where do we stand today? Journal of Gastrointestinal Surgery: Official Journal of the Society for Surgery of the Alimentary Tract. 2012; 16: 2203–2211. https://doi.org/10.1007/s11605-012-2049-5

[5] Oka A, Awoniyi M, Hasegawa N, Yoshida Y, Tobita H, Ishimura N, et al. Superior mesenteric artery syndrome: Diagnosis and management. World Journal of Clinical Cases. 2023; 11: 3369–3384. https://doi.org/10.12998/wjcc.v11.i15.3369

[6] Sabry A, Shaalan R, Kahlin C, Elhoofy A. Superior Mesenteric Artery Syndrome Managed with Laparoscopic Duodenojejunostomy. Minimally Invasive Surgery. 2022; 2022: 4607440. https://doi.org/10.1155/2022/4607440

[7] Lu SB, Guo YQ, Chen RY, Zhang YF. Laparoscopic Surgery for Superior Mesenteric Artery Syndrome. Journal of Investigative Surgery: the Official Journal of the Academy of Surgical Research. 2024; 37: 2387524. https://doi.org/10.1080/08941939.2024.2387524

[8] Chang J, Boules M, Rodriguez J, Walsh M, Rosenthal R, Kroh M. Laparoscopic duodenojejunostomy for superior mesenteric artery syndrome: intermediate follow-up results and a review of the literature. Surgical Endoscopy. 2017; 31: 1180–1185. https://doi.org/10.1007/s00464-016-5088-2

[9] Sun Z, Rodriguez J, McMichael J, Walsh RM, Chalikonda S, Rosenthal RJ, et al. Minimally invasive duodenojejunostomy for superior mesenteric artery syndrome: a case series and review of the literature. Surgical Endoscopy. 2015; 29: 1137–1144. https://doi.org/10.1007/s00464-014-3775-4

[10] Mandarry MT, Zhao L., Zhang C., Wei ZQ. A comprehensive review of superior mesenteric artery syndrome. European Surgery. 2010; 42: 229–236. https://doi.org/10.1007/s10353-010-0561-y

[11] Bloodgood JC. X. Acute Dilatation of the Stomach-Gastro-mesenteric Ileus. Annals of Surgery. 1907; 46: 736–762. https://doi.org/10.1097/00000658-190711000-00011

[12] Camilleri M, Chedid V, Ford AC, Haruma K, Horowitz M, Jones KL, et al. Gastroparesis. Nature Reviews. Disease Primers. 2018; 4: 41. https://doi.org/10.1038/s41572-018-0038-z

[13] Stanghellini V, Chan FKL, Hasler WL, Malagelada JR, Suzuki H, Tack J, et al. Gastroduodenal Disorders. Gastroenterology. 2016; 150: 1380–1392. https://doi.org/10.1053/j.gastro.2016.02.011

[14] Cienfuegos JA, Hurtado-Pardo L, Valentí V, Landecho MF, Vivas I, Estévez MG, et al. Minimally Invasive Surgical Approach for the Treatment of Superior Mesenteric Artery Syndrome: Long-Term Outcomes. World Journal of Surgery. 2020; 44: 1798–1806. https://doi.org/10.1007/s00268-020-05413-5

[15] Jain N, Chopde A, Soni B, Sharma B, Saini S, Mishra S, et al. SMA syndrome: management perspective with laparoscopic duodenojejunostomy and long-term results. Surgical Endoscopy. 2021; 35: 2029–2038. https://doi.org/10.1007/s00464-020-07598-1

[16] Aneiros Castro B, Cano Novillo I, García Vázquez A, Martín Alelu R, Gómez Fraile A. Wilkie's syndrome in monozygotic twins treated by 3-D laparoscopic duodenojejunostomy. Asian Journal of Endoscopic Surgery. 2019; 12: 125–127. https://doi.org/10.1111/ases.12489

[17] Ganss A, Rampado S, Savarino E, Bardini R. Superior Mesenteric Artery Syndrome: a Prospective Study in a Single Institution. Journal of Gastrointestinal Surgery: Official Journal of the Society for Surgery of the Alimentary Tract. 2019; 23: 997–1005. https://doi.org/10.1007/s11605-018-3984-6

[18] Zihni AM, Dunst CM, Swanström LL. Surgical Management for Gastroparesis. Gastrointestinal Endoscopy Clinics of North America. 2019; 29: 85–95. https://doi.org/10.1016/j.giec.2018.08.006

[19] Bhayani NH, Sharata AM, Dunst CM, Kurian AA, Reavis KM, Swanstrom LL. End of the road for a dysfunctional end organ: laparoscopic gastrectomy for refractory gastroparesis. Journal of Gastrointestinal Surgery: Official Journal of the Society for Surgery of the Alimentary Tract. 2015; 19: 411–417. https://doi.org/10.1007/s11605-014-2609-y

[20] Welsch T, Büchler MW, Kienle P. Recalling superior mesenteric artery syndrome. Digestive Surgery. 2007; 24: 149–156. https://doi.org/10.1159/000102097

[21] Lee CS, Mangla JC. Superior mesenteric artery compression syndrome. The American Journal of Gastroenterology. 1978; 70: 141–150.

© 2026 The Author(s).

