

Chorda Tympani nerve injury during tympanoplasty. Comparison of endoscopic and microscopic methods



Ann Ital Chir, 2021 92, 2: 119-122

pii: S0003469X2102813X

Online ahead of print 2021 - Mar. 2

free reading: www.annitalchir.com

Ismail Iynen*, Riza Dündar**

*Harran University, Faculty of Medicine, Department of Otorhinolaryngology, Şanlıurfa, Turkey

**Acibadem University, Vocational School of Health Sciences Eskişehir Hospital, Department of Otorhinolaryngology, Eskişehir, Turkey

Chorda Tympani nerve injury during tympanoplasty. Comparison of endoscopic and microscopic methods

PURPOSE: Iatrogenic injury of the chorda tympani nerve (CTN) is a well-recognized complication of middle ear surgery. The aim of the present study was to compare CTN injury occurring as a result of type 1 tympanoplasty performed using microscopic and endoscopic methods.

METHODS: A retrospective study was conducted at our institution on patients diagnosed with chronic otitis and then treated with type 1 tympanoplasty surgery between January, 2013 and January, 2014. The patients were divided into two groups; group 1 consisted of patients who underwent endoscopic tympanoplasty and group 2 consisted of patients who underwent microscopic tympanoplasty. At follow-up 3, 6, and 12 months after surgery patients were asked to complete a questionnaire that enquired about symptoms of CTN injury: changes in taste sensation, tongue numbness, and dry mouth.

RESULTS: There were 66 patients (33 males, mean age 30.4 ± 8.14 years (range: 8-56 years)). There were 25 patients in group 1 (endoscopic tympanoplasty) and 41 patients in group 2 (microscopic tympanoplasty). A total of 11 (16.6%) patients reported symptoms related to CTN damage: 1 (4%) patient in group 1 and 10 (24%) patients in group 2. A metallic taste in the mouth was the most-common symptom, noted by 7 patients (63.6%), 1 (4%) in group 1 and 6 (14.6%) in group 2. Ageusia/hypogeusia was reported by 4 patients (37.4%) all in group 2. Tongue numbness occurred in 2 patients (4.8%) in group 2. No patients had xerostomia.

CONCLUSIONS: Type 1 tympanoplasty performed with an endoscopic technique is minimally invasive, and is associated with less CTN manipulation and as a consequence less iatrogenic injury to the CTN.

KEY WORDS: Chorda Tympani Nerve, Endoscopic Tympanoplasty, Microscopic Tympanoplasty, type 1 Tympanoplasty

Introduction

The chorda tympani nerve (CTN) is a branch of the facial nerve within the middle ear. It is a mixed nerve that has a sensory component which supplies taste by innervating the fungiform papillae on the anterior two

thirds of the tongue and a secretomotor component which contains preganglionic parasympathetic axons that innervate the submandibular and sublingual glands. Within the middle ear, it lacks a bony covering as it passes close to the annulus of the tympanic membrane, between the incus and the malleus. Its exposed course through the middle ear may make it prone to damage by disease processes affecting that space. Iatrogenic CTN injury is a well-recognized complication of middle ear surgery. There may be situations in which the nerve has been damaged preoperatively by disease (i.e., chronic otitis media and cholesteatoma) ¹.

During middle ear surgery, several important structures may be encountered within the surgical site, including the sigmoid sinus on the posterior side, dura mater on the superior side and part of the petrous carotid canal

Pervenuto in Redazione Dicembre 2017. Accettato per la pubblicazione Giugno 2018

Correspondence to: Ismail Iynen, Assoc. Prof. Harran University, Medical Faculty Department of Otorhinolaryngology, 63100, Şanlıurfa, Turkey (e-mail: iynen@hotmail.com)

on the anterior side, as well as the facial nerve and CTN. CTN damage is more frequently observed than damage to other structures. The CTN can be injured during several types of middle ear surgery including canal wall-up and wall-down procedures, meatoplasty and otosclerosis operations². The most common symptoms of CTN injury reported are changes in taste sensation and xerostomia². CTN injury during middle ear surgery occurs particularly during operations requiring precise visualization of the ossicular chain. It is frequently necessary to excise the chordal crest, an area of bony tissue located near to where the CTN enters the middle ear. Chordal crest resection is frequently performed during operations using a microscope. During tympanic annulus elevation, CTN injury may also develop following the use of surgical instruments including aspirators and straight-picks. Injury severity varies, but may include complete transection. Endoscopy, the use of which has become more frequent in ear surgery in the past two decades, allows for clear imaging of the ossicular chain, particularly when using angulated endoscopes during tympanoplasty and ossiculoplasty procedures. Endoscopy has rendered chordal crest resection and CTN manipulation less necessary, thereby minimizing iatrogenic CTN injury^{3,4}. In this study, we compared CTN injury during type 1 tympanoplasty operations performed with microscopic and endoscopic techniques.

Materials and Methods

This retrospective study was conducted following approval from the Ethics Committee of the Harran University School of Medicine, Turkey (clinical study number:74059997.050.01.04/199). Patients who presented to the Ear Nose and Throat and Head and Neck Surgery clinics of the Harran University School of Medicine between January, 2013 and January, 2014, with chronic otitis and then underwent type 1 tympanoplasty (repair of the tympanic membrane without manipulation of the ossicular chain) were identified. Data from a prospectively maintained database were retrospectively analysed. Patients who underwent revision surgery, and those with a history of otological trauma or with ossicle destruction and cholesteatoma, were excluded. Patients were divided into two groups; group 1 included patients treated with endoscopic tympanoplasty and group 2 included patients treated with microscopic tympanoplasty. Manipulation of the CTN during surgery was classified as follows: manipulated, not manipulated or incised (Table I). At follow-up 3, 6, and 12 months after surgery patients were asked to complete a questionnaire that enquired about symptoms of CTN injury: changes in taste sensation, tongue numbness and dry mouth (Table I).

STATISTICAL ANALYSIS

Categorical variables were compared using two tailed Fisher's exact test. A p value < 0.05 was considered statistically significant.

SURGICAL TECHNIQUE

The tympanoplasty procedures were performed by the same ear surgeon under general anesthesia. None of the patients underwent bilateral tympanoplasty. In group 1, an endoscopic system (Karl Storz; Tuttlingen, Germany) and rigid endoscopes [2.7 mm (6.0 cm) and 4.0 mm (16.0 cm); Karl Storz; Tuttlingen, Germany] were used. After de-epithelialization of the margins of the perforation, an incision was made laterally in the posterior and inferior parts of the external auditory canal (about 6 to 8 mm from the tympanic membrane). A tympanomeatal flap was elevated, and the middle ear cavity was visualized (Fig. 1). A piece of chondroperichondrial graft was taken from the tragus and was stretched and pressed and the "underlay" graft was placed medial to the malleus. In Group 2, a microscope (Opmi Vario/s88; Carl Zeiss, Oberkochen, Germany) was used and a retroauricular or endaural approach was employed. After creating the endaural or retroauricular incision, a tympanomeatal flap was elevated, the middle ear cavity revealed (Fig. 2). A piece of chondroperichondrial graft was taken from the tragus and was stretched and pressed and the "underlay" graft was placed medial to the malleus.

Results

There were 66 patients (33 males) with a mean age of 30.4 ± 8.14 years (range: 8-56 years). Group 1 consisted of 25 patients (11 males,) with a mean age of 28.35 ± 6.14 years (range: 11-45 years). Group 2, consisted of 41 patients (22 males) with a mean age of 32.35 ± 10.14 years (range: 9-56 years). No patients in group 1 required chordal crest removal, because the ossicular chain could be fully visualized using the endoscopic system. In group 2, 18 (53%) patients underwent removal of the chordal crest using a curette or drill to allow for visualization of the ossicular chain. The CTN was manipulated during annulus elevation in 8 patients in group 1 (32%), None of the patients in group 1 experienced CTN transection whereas 3 patients (7%) in group 2 experienced accidental transection of the nerve (p=0.28) (Table I). All patients completed the questionnaire at 3, 6 and 12 months after surgery. A total of 11 (16.6%) patients reported symptoms related to CTN damage: 1 (4%) in group 1 vs.10 (24.3%) in group 2 (including the 3 patients with an accidentally transected CTN) (p=0.03). Altered sense of taste was the most-common symptom; a

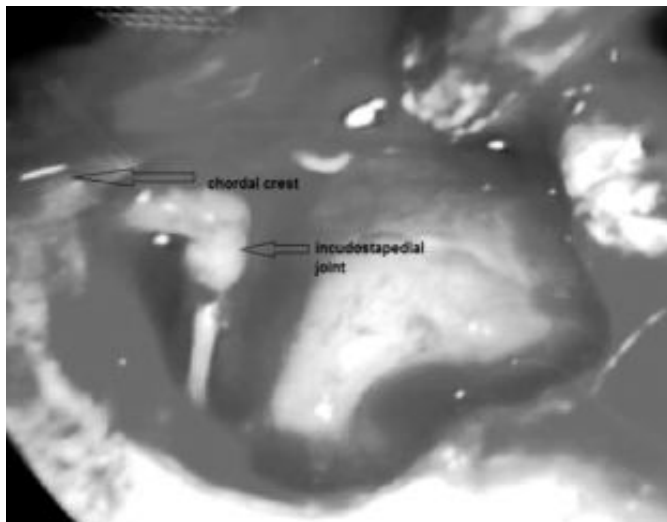


Fig. 1: View of middle ear during endoscopic tympanoplasty(chorda tympani nerve not manipulated).

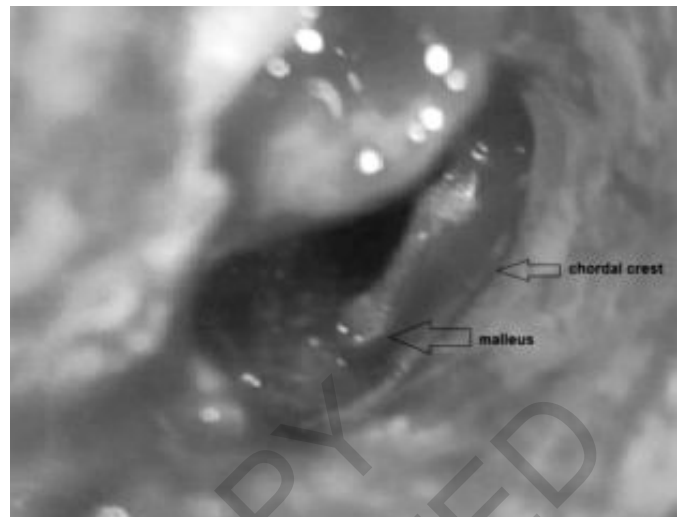

Fig. 2: View of middle ear during microscopic tympanoplasty(chorda tympani nerve not manipulated).

metallic taste in the mouth was reported by 7 patients (10.6%): 1 in group 1 (4%) and 6 in group 2 (14.6%) ($p=0.29$). Ageusia/hypogeusia was reported by 4 patients (6%) in group 2 (37.4%) but none in group 1 ($p=0.28$). (Table I). Tongue numbness was reported by 2 patients in group 2 (5%) but none in group 1 ($p=0.52$) (Table I). No patients had xerostomia. No patients had more than one symptom of CTN damage.

At 6-month follow-up the metallic taste in the mouth reported by 1 patient in group 1 had resolved. In group 2, all 6 patients who had described a metallic taste in the mouth reported that this symptom had resolved.

At 12-month follow-up all 4 patients in group 2 who had described ageusia/hypogeusia reported that this symptom had resolved. The only symptom of CTN injury which persisted at 12 months was tongue numbness, reported by 2 patients in group 2.

Discussion

Iatrogenic damage to the CTN is a well recognised complication of middle ear surgery. Altered taste perception following CTN trauma has been reported in 15-22% of patients². However these complications are usually not persistent. Gopalan et al reported that symptoms of CTN injury after middle ear surgery ceased within 4-8 months⁵. In a study conducted by Michael et al., 11% (7/56) of the patients treated with tympanoplasty/myringoplasty reported postoperative alterations in taste perception due mostly to excessive manipulation of the nerve and a period of 12 months was required for full recovery⁴. The consequences of injury are variable, prognosis is difficult to predict, and methods of prevention are sometimes controversial. It is hard to determine the rate of

CTN injury which depends on the time of diagnosis, the underlying disease, and the surgical procedure and technique used. Mechanisms by which the CTN may be damaged during surgery include transection (accidental or deliberate), stretching, ischemia, thermal injury, excessive handling and desiccation. Stretching occurs frequently, for instance when raising a tympanomeatal flap during myringoplasty⁷.

Type 1 tympanoplasty is a surgical procedure frequently performed during otology; the-most important tool for visualization is the surgical microscope, which allow the surgeon to work with both hands and confers advantages with respect to sense of depth and provision of a three-dimensional view. However, one disadvantage is that both the patient's head and the microscope must be repositioned frequently⁸. Another technique that has gained popularity in otological surgery during the past two decades is the endoscopic approach. Endoscopic type 1 tympanoplasty has frequently been performed in recent years, with several successful outcomes reported⁹. There are also disadvantages associated with endoscopic surgery; for example, the surgeon can only use one hand, and the two-dimensional view is associated with difficulties in depth perception. However, endoscopy is minimally invasive, and allows for easy visualization of sites that are difficult to observe using a microscope^{4,10,11}.

Less postoperative complications have been recorded after endoscopic tympanoplasty¹⁰. Lade et al. evaluated 30 patients who underwent type 1 tympanoplasty using microscopic methods, and 30 patients treated using the endoscopic method. Groups were compared with respect to the curettage of the posterosuperior wall of the external auditory canal (i.e.,the chordal crest). Curettage was required in 5 of 30 microscopic method patients, but in no patient treated with an endoscopic technique.

Canalplasty was performed in 5 microscopic method patients³. Similarly, in our study, 18 (53%) patients in the microscopic group underwent chordal crest curettage but this was not required in any endoscopic surgery patient.

Curettage interventions using a drill or curette may result in CTN injury, leading to altered taste perception and tongue numbness¹². In a study by Matthew et al., CTN manipulation was performed in 14 (73%) of 19 type I tympanoplasty patients, with complete CTN transection in 2 cases (10.5%). During the postoperative period, 12 patients reported symptoms related to sense of taste¹. Hunter et al. reported that there was no damage to the CTN in any of their cases of endoscopic tympanoplasty and no postoperative taste disturbance or other symptoms of CTN injury¹³. Saito et al. reported that only 39 % of patients with a severely damaged CTN complained of postoperative taste alteration, even though all patients' electrogustometry results indicated no taste response whatsoever¹⁴.

In our study, CTN manipulation was performed in all 41 patients who underwent microscopic intervention. The CTN was cut accidentally in 3 of these patients. Ten patients reported postoperative alterations in taste perception. In the group that underwent endoscopic intervention, CTN manipulation was performed in only 8 patients, one of whom reported altered taste perception. These findings suggest that the risk of CTN injury during type I tympanoplasty can be minimized if an endoscopic technique is used. When endoscopy cannot be performed for anatomical reasons (e.g., due to an insufficiently wide external auditory canal that cannot accommodate the endoscope and other instrumentation), endoscope-assisted tympanoplasty can be performed, which may prevent complications resulting from CTN injury, that although not life-threatening and usually not permanent nevertheless affect patients' quality of life. A limitation of our study, besides the retrospective study design, was that only subjective measurements were employed to assess the degree of CTN manipulation and postoperative complications associated with CTN injury. Electrophysiological studies could provide more accurate quantification.

Conclusion

In contrast to microscopic type I tympanoplasty, the endoscopic approach is minimally invasive, associated with a reduced degree of CTN manipulation and as a consequence associated with less iatrogenic injury to the CTN. Further studies are needed to confirm our results.

References

1. Clark MPA O'Malley S: *Chorda tympani nerve function after middle ear surgery*. *Otology & Neurotology*, 2007; 28:335-39.
2. McManus LJ, Stringer MD, Dawes PJ: *Iatrogenic injury of the chorda tympani: A systematic review*. *J Laryngol Otol*, 2012;126:8-14.
3. Lade H, Choudhary SR, Vashishth A: *Endoscopic vs microscopic myringoplasty: A different perspective*. *Eur Arch Otorhinolaryngol*. 2014; 271:1897-902.
4. Ayache S: *Cartilaginous myringoplasty: The endoscopic transcanal procedure*. *Eur Arch Otorhinolaryngol*, 2013; 270:853-60.
5. Gopalan P, Kumar M, Gupta D, et al.: *A study of chorda tympani nerve injury and related symptoms following middle-ear surgery*. *J Laryngol Otol*, 2005; 119:189-92.
6. Michael P, Raut V: *Chorda tympani injury: operative findings and postoperative symptoms*. *Otolaryngol Head Neck Surg*, 2007; 136:978-81.
7. A Rehman, S Hamid, M Sangoo, et al.: *Short term and long term subjective taste disorder after middle ear cleft surgery*. *Indian Journal of Otology*, 2013; 19:3, 111-13.
8. Mohindra S, Panda NK: *Ear surgery without microscope; is it possible*. *Indian J Otolaryngol Head Neck Surg*, 2010; 62:138-41.
9. Usami S, Iijima N, Fujita S, Takumi Y: *Endoscopic assisted myringoplasty*. *J Otorhinol Relat Spec* 2001; 63:287-90.
10. Harugop AS, Mudhol RS, Godhi RA: *A comparative study of endoscope assisted myringoplasty and microscope assisted myringoplasty*. *Indian J Otolaryngol Head Neck Surg*, 2008; 60:298-302.
11. Tseng CC, Lai MT, Wu CC, Yuan SP, Ding YF: *Cost-effectiveness analysis of endoscopic tympanoplasty versus microscopic tympanoplasty for chronic otitis media in Taiwan*. *J Chin Med Assoc*, 2018; 81(3):284-290. doi: 10.1016/j.jcma.2017.06.024. Epub 2017 Dec 26.
12. Bartoshuk L: *Clinical evaluation of the sense of taste*. *Ear Nose Throat J*, 1989; 68:331-37.
13. Hunter JB, O'Connell BP, Rivas A: *Endoscopic techniques in tympanoplasty and stapes surgery*. *Curr Opin Otolaryngol Head Neck Surg*, 2016; 24(5):388-94. doi: 10.1097/MOO.0000000000000297.
14. Saito T, Manabe Y, Shibamori Y, Yamagishi T, Igawa H, Tokuriki M, et al.: *Long-term follow-up results of electrogustometry and subjective taste disorder after middle ear surgery*. *Laryngoscope*, 2001; 111:2064-70.