

Appendectomy with Single-Port laparoscopic transumbilical surgery



Ann. Ital. Chir., 2011 82: 421-425

Baki Ekçi

Yeditepe University, Faculty of Medicine, Department of General Surgery, Istanbul, Turkey

Appendectomy with Single-Port laparoscopic transumbilical surgery

PURPOSE: Acute appendicitis is among the most common emergency conditions in surgical practice and appendectomy is the most common treatment. Single-port (SP) laparoscopic transumbilical surgery has emerged in clinical practice. The aim of this study is to describe SP laparoscopic transumbilical surgery procedure performed in three patients undergoing appendectomy.

METHODS: Three patients diagnosed with acute appendicitis were operated with SP laparoscopic transumbilical surgery technique. Patient's gender, age, BMI, operation time and length of hospital stay were recorded.

RESULTS: Three patients (2 female, 1 male) with a mean age of 38 (range 28-48) years underwent appendectomy. The mean postoperative length of stay was 1 day. The mean operative time was 35 minutes (range 30-45 minutes). No scar formation was observed and incisions were nearly invisible in the umbilicus in all patients.

CONCLUSION: SP laparoscopic transumbilical appendectomy is a safe, effective and reliable technique leading potentially scarless abdominal surgery. Even though SP laparoscopic transumbilical surgery cannot substitute laparoscopic appendectomy for the moment, it is assumed that this procedure will become widespread by putting novel instruments into practice.

KEY WORDS: Appendectomy, Single-Port laparoscopic transumbilical surgery.

Introduction

Acute appendicitis is a common indication for abdominal surgery with a lifetime incidence between 7 and 9%¹, and appendectomy is the most common treatment. Open appendectomy procedure was first described in 1894². It has become the standard treatment of choice for acute appendicitis. To present, this technique has remained mainly unchanged due to its favorable efficacy and safety.

Globalization has led the quick spread of improvements within the field of surgery to reach the aim of enhancing benefit and safety. As these advances access a wider population, a greater acceptance of and expectation from new surgical techniques arise. In 1998, the two-port technique was introduced by Schier³ who used an intracorporeal appendectomy approach with a special operative telescope in children. Furthermore, other variant methods have been described in adults. Laparoscopic appendectomy was first described in 1983 by Kurt Semm⁴. Recently, Single-port (SP) laparoscopic transumbilical surgery has emerged in clinical practice. This surgery is one of the newest branches of advanced laparoscopy. The procedure is performed in a fashion similar to conventional laparoscopy⁵. The primary goal is to avoid visible scarring. SP laparoscopic transumbilical surgery provides patients not only a "scarless surgery" leading to a better cosmetic result, but also the benefit of reducing opera-

Pervenuto in Redazione Febbraio 2011. Accettato per la pubblicazione Aprile 2011

Correspondence to: Baki Ekçi M.D., PTT hastanesi Karşıtı, Evren sitesi B Blok D: 87, İçerenköy, İstanbul, Turkey 34752 (e-mail: drbaki@yahoo.com).

tive site pain and infection. For the aim of reducing incisional morbidity and enhancing cosmesis, various modified techniques, involving fewer and smaller incisions, have been introduced.

The aim of this study is to describe SP laparoscopic transumbilical appendectomy procedure performed in three patients.

Material and method

Three patients who referred to the emergency department of Yeditepe University Hospital with a chief complaint of abdominal pain were included to the study. During the evaluation process, acute appendicitis was diagnosed in all three patients. One of the patients had perforated acute appendicitis. 3 patients (2 female, 1 male) with a mean age of 38 (range 28-48) years underwent SP laparoscopic transumbilical appendectomy. The patients fully consented to the operation and each patient also signed a detailed informed consent form. The patients were also informed that as an initial procedure, this technique would bring them no benefit, but it would reduce the wound size relatively. Furthermore, they were fully aware that in the event of intraoperative difficulty or complication, an additional port would be used or the operation would be converted to open surgery. All three patients were operated with single incision laparoscopy. Appropriate antibiotics therapy were given to all three patients pre- and postoperatively.

Surgical Procedure of Appendectomy with SP laparoscopic transumbilical surgery

The patient was placed in the reverse Trendelenburg position with his/her left side downwards and the left arm closed laterally. The surgeon and assistant stand on the left side of the patient, while nurse stand on the down-side (Fig. 1). The camera holder might stand on the right side of the operator. Under the general anesthesia, umbilicus was averted using with Kocher clamps. Using the open Hasson technique, a 2.5-cm vertical incision was made through the umbilicus. Linea alba was dissected down. Peritoneum was opened under direct vision. Then, the SP laparoscopic transumbilical port (SILS™ Port 12mm, Covidien, USA) was inserted from this defect. All surgical procedures were performed intracorporeally. Under the guide of the laparoscope, a routine exploration was performed. Another alternative is the insertion of a 10-mm trocar and 2 of 5-mm trocars through the same incision line. Pneumoperitoneum was initiated to a pressure of 12 mm Hg. A 5-mm or 10-mm rigid type laparoscope was used for visualization throughout the procedure and a full diagnostic laparoscopy was performed for all patients. A 5-mm roticulating grasper (Roticulator Endo Grasp™

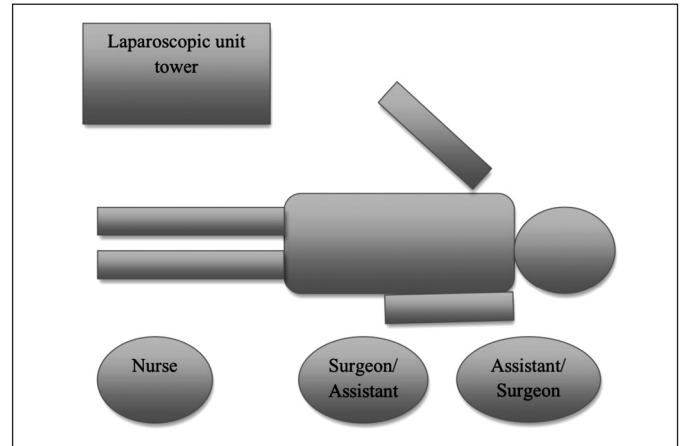


Fig. 1: Surgical team localization.

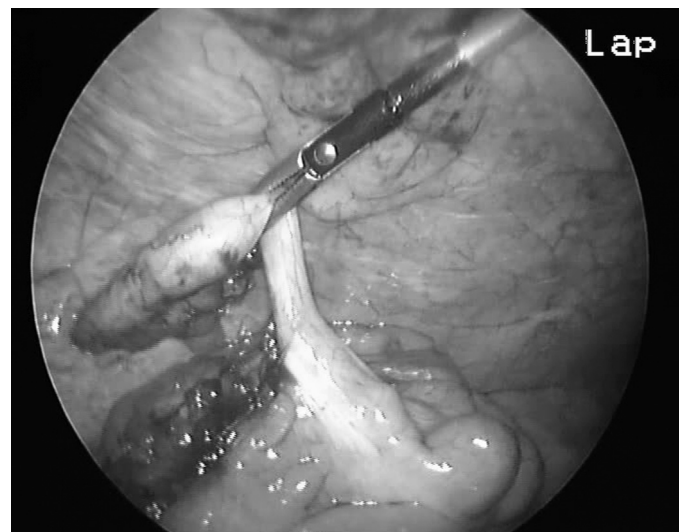


Fig. 2: Roticulating grasper holds appendix and helps to move in any direction.

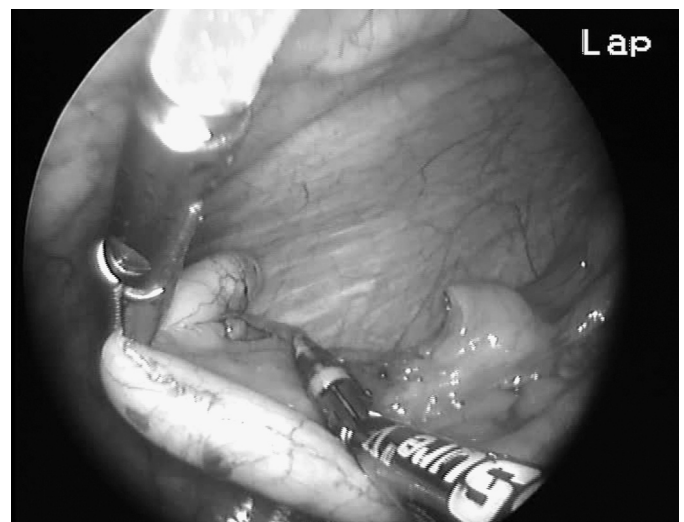


Fig. 3: Ligature was used to dissect the mesentery of the appendix.

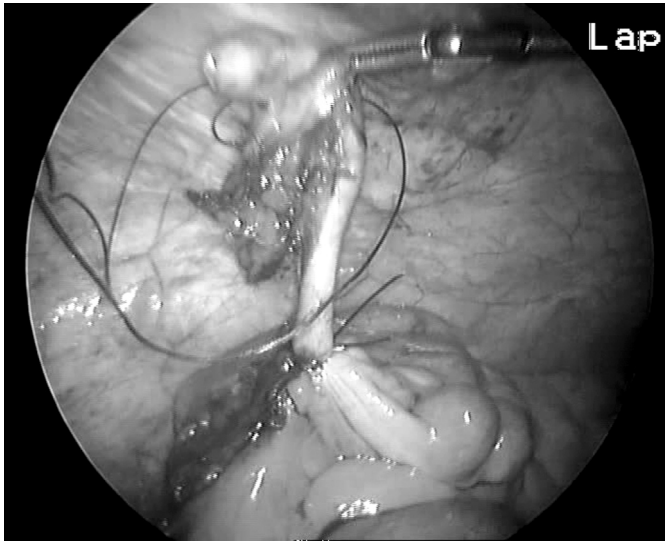


Fig. 4: Two vicryl endoloops were put to close the base of the appendix.

with Lock, Covidien, USA) was then introduced through the port and it was used to retract the bowel and expose the appendix. It held appendix and helped to move upward and medially/laterally (Fig. 2). Dissection of the appendix was started where the meso of appendix appeared. A 5-mm Ligasure or hook was used to dissect the mesentery of the appendix (Fig. 3). After sealing the artery and vein, two vicryl endoloops were put to close the base of the appendix (Fig. 4). Appendectomy line was inspected for hemostasis and leakage. After that, endobag (Endo Catch, Covidien, USA) was used to extract the appendix. If required, abdomen might be irrigated with a 5-mm aspirator/irrigation. The abdomen was deflated and the fascial defect was closed with a figure of eight by a 2/0 non-absorbable suture. The skin incision was then closed with a 3/0 absorbable/non-absorbable suture. Should the occasion arise, abdominal drain might be placed into the same/another incision.

Results

Overall, 3 patients (2 female, 1 male) with a mean age of 38 (range 28-48) years underwent SP laparoscopic transumbilical appendectomy. Patient and operation's data are shown in Table I. None of the patients had undergone previous abdominal surgery. All patients' abdomen was lubricated with sterile saline solution. An intraabdominal drain was placed to the patient who had generalized peritonitis. Then, the drain was removed at the day of discharge. All 3 procedures were successful without intraoperative or early postoperative complications and no port site hernias were noted in the immediate postoperative period. Transumbilical incisions of all 3 patients were controlled at postoperative 10th day. No scar formation was observed and incisions were nearly

TABLE I - Patient and operation's data.

	Case 1	Case 2	Case 3
Age	38	48	28
Gender(male/female)	F	F	M
Operating time (min)	35	45	30
Body Mass Index (kg/m ²)	24	25	24.2
Postoperative hospital stay (day)	1	1	1

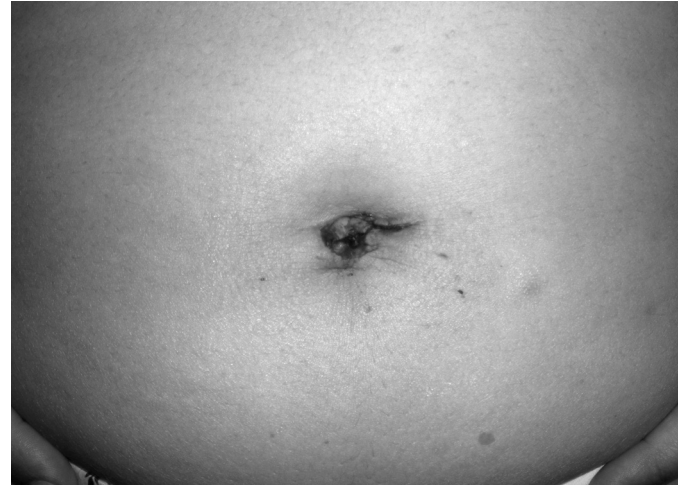

Fig. 5: Incisions are nearly invisible in the umbilicus.

invisible in the umbilicus (Fig. 5). The mean postoperative length of stay was 1 day. The mean operative time was 35 minutes (range 30-45 minutes).

Discussion

With the beginning of the 20th century, great alterations have occurred in medicine by the continuous development of science and technology. The field of surgery has experienced great changes within approximately the last 50 years. Mortality and morbidity rates have decreased parallel to the improvement of surgical techniques, treatment methods, and novel drugs. Once upon a time, the expression "big scar - big surgeon" was used to define the excellence of surgery. With the perception of beauty and esthetics, this expression has lost its validity over time. After the first laparoscopic appendectomy and cholecystectomy operation, this intervention has led the beginning of a new age in surgery^{6,7}. With the advances in laparoscopic technique, big incisions were replaced with 3 or 4-port surgery.

Acute appendicitis is among the most common emergency conditions in surgical practice. This condition may occur at any age and it necessitates surgical treatment in every case when diagnosed¹. Open appendectomy procedure was first described in 1894². This procedure has

been widely used until today. However, with the advancement of novel techniques and instruments, less mortality and morbidity rates, cosmesis, and shorter hospital stay have become possible after surgery. The first laparoscopic appendectomy was performed by Semm⁴ in 1983, and since then it has gradually gained acceptance. With the benefits of better visualization, cosmesis and producing less postoperative pain, laparoscopic surgery has become a popular treatment option for appendicitis. In many studies, laparoscopic surgery provides considerable benefits over open surgery, including lower complication rates, short duration of hospital stay postoperatively, less surgical-site infection, and better cosmesis^{8,9}.

Recently, SP laparoscopic transumbilical surgery has emerged in clinical practice. The main benefit of SP is its potential to enhance postoperative recovery period and to provide potentially "scarless" surgery, since the surgical scar may often be well-hidden within the umbilicus. Without doubt, this technique is physiologically less traumatic than the conventional approach, because no incision is made into the abdomen through muscles. In addition, it also eliminates any possible injury to the bladder, inferior epigastric vessels and huge abdominal wall hematoma, incisional bleeding, intestinal perforation⁹⁻¹². The experience with the present cases indicated that the incision should be created relatively deep in the umbilicus to help hide the resulting scar. The SP laparoscopic transumbilical surgery necessitates laparoscopic skills at an advanced level. The presence of a single access and the use of multiple instruments may impede the continuity of the surgical procedure¹³⁻¹⁶. For overcoming such difficulties, surgeons have developed some individual techniques to make the procedure more feasible. Teaching this technique to trainees capable of conventional laparoscopic appendectomy is simple and has a short learning curve.

Initial experience with three patients who underwent SP laparoscopic transumbilical appendectomy indicated that this technique was safe and applicable compared with the conventional appendectomy technique. In terms of cosmetics, this technique results with an almost invisible scar as observed in the present study. Thereby, patients are less traumatized and feel comfortable because they do not have any visible scars on their abdomen. Overall, the level of satisfaction was greater with this technique. It is assumed that there is less pain and less bleeding from the trocar sites postoperatively. The limitations of SP laparoscopic transumbilical appendectomy are incisional hernia risk, limited visualization and interference of the instruments. There has been no published data regarding increased incisional hernia risk in SP until today. However, the larger incision of the fascia in this technique might be associated with incisional hernia risk. During the procedure, all instruments and camera are inserted through the same port causing limited visualization. Moreover, this situation results with the loss of the ability to triangulate the instruments

around the target. However, this problem may be overcome with the use of roticulator instruments.

In consequence, SP laparoscopic transumbilical appendectomy is a safe, effective and reliable technique leading potentially scarless abdominal surgery. Even though SP laparoscopic transumbilical surgery cannot substitute laparoscopic appendectomy for the moment, it is assumed that this procedure will become widespread by putting novel instruments into practice. This technique seems to be more preferable as it results with less incision scar and less pain. However, further prospective studies involving more clinical cases are required to confirm all these favorable outcomes.

Riassunto

L'appendicite acuta è tra le più comuni condizioni di emergenza chirurgica e l'appendicectomia è l'intervento chirurgico più frequente. La chirurgia laparoscopica transombelicale ad unico accesso (SP) si è ormai accreditata nella pratica clinica. Lo scopo del presente studio è quello di illustrare la procedura di chirurgia laparoscopica transombelicale SP adottata in tre pazienti sottoposti ad appendicectomia, dopo la diagnosi di appendicite acuta.

Si trattava di 2 donne ed 1 uomo, dell'età media di 38 anni. La durata della degenza postoperatoria è stata di un giorno, e la durata dell'intervento è stata in media di 35 minuti, con assenza di formazioni cicatriziali e praticamente invisibili le incisioni vicino all'ombelico.

Si ritiene che la appendicectomia laparoscopica transombelicale SP sia una procedura sicura, efficace ed affidabile che ottiene risultati potenzialmente privi di cicatrici.

Anche se questa tecnica non può attualmente sostituire l'appendicectomia laparotomica, si ritiene che la procedura sia destinata ad una larga diffusione con l'introduzione di una nuova strumentazione nell'uso comune.

References

- 1) Addiss DG, Shaffer N, Fowler BS, Tauxe RV: *The epidemiology of appendicitis and appendectomy in the United States*. Am J Epidemiol, 1990; 132:910-25.
- 2) McBurney C: *The incision made in the abdominal wall in cases of appendicitis, with a description of a new method of operating*. Ann Surg, 1894; 20:38-43.
- 3) Schier F: *Laparoscopic appendectomy with 1.7-mm instruments*. Pediatr Surg Int, 1998; 14:142-43.
- 4) Semm K: *Endoscopic appendectomy*. Endoscopy, 1983; 15:59-64.
- 5) MacDonald ER: *Ahmed I. Technical note: Single-port laparoscopic appendectomy*. Ann R Coll Surg Engl, 2009; 91:519-20.
- 6) Chung RS, Rowland DY, Li P, Diaz J: *A meta-analysis of randomized, controlled trials of laparoscopic versus conventional appendectomy*. Am J Surg, 1999; 177:250-56.

- 7) Polychronidis A, Laftsidis P, Bounovas A, Simopoulos C: *Twenty years of laparoscopic cholecystectomy: Philippe Mouret-March 17, 1987*. JSLS, 2008; 12:109-11.
- 8) Xiaohang L, Jialin Z, Lixuan S, Wenliang Z, Zhiqiang C, Xin L, Yongfeng L: *Laparoscopic versus conventional appendectomy. A meta-analysis of randomized controlled trials*. BMC Gastroenterol, 2010; 10:129-36.
- 9) Wu HS, Lai HW, Kuo SJ, Lee YT, Chen DR, Chi CW, Huang MH: *Competitive Edge of Laparoscopic Appendectomy Versus Open Appendectomy: A Subgroup Comparison Analysis*. J Laparoendosc Adv Surg Tech A, 2011; [Epub ahead of print].
- 10) Varlet F, Tardieu D, Limonne B, Metafiot H, Chavrier Y: *Laparoscopic versus open appendectomy in children-comparative study of 403 cases*. Eur J Pediatr Surg, 1994; 4:333-37.
- 11) Fernández EM, Malagón AM, Arteaga I, Díaz H, Carrillo A: *Conservative treatment of a huge abdominal wall hematoma after laparoscopic appendectomy*. J Laparoendosc Adv Surg Tech A, 2005; 15:634-37.
- 12) Schäfer M, Lauper M, Krähenbühl L: *Trocar and Veress needle injuries during laparoscopy*. Surg Endosc, 2001; 15:275-80.
- 13) Ekçi B: *A simple technique for knot tying in single incision laparoscopic surgery (SILS)*. Clinics (Sao Paulo), 2010; 65:1055-57.
- 14) Thanakumar J, John PH: *One-handed knot tying technique in single-incision laparoscopic surgery*. J Minim Access Surg, 2011; 7:112-15.
- 15) Udwardia TE: *Single-incision laparoscopic surgery: An overview*. J Minim Access Surg, 2011; 7:1-2.
- 16) Cuschieri A: *Single-incision laparoscopic surgery*. J Minim Access Surg, 2011; 7:3-5.

